

A 51-Year-Old Woman with Right Dorsal Foot Pain

Sheng-Hao Cheng, Tyng-Guey Wang*

Department of Physical Medicine and Rehabilitation, National Taiwan University Hospital and National Taiwan University College of Medicine, Taipei, Taiwan

SECTION 1 – QUIZ

A 51-year-old woman had insidious painful sensation over her right dorsal foot. The pain aggravated in walking. Physical examination showed mild swelling of the right dorsal foot without concurrent erythema or local heat but exaggerative pain when squeeze tests were performed. The Tinel's sign at the right dorsal foot was negative. The following ultrasound images showed the transverse and longitudinal views of the right dorsal foot [Figure 1].

WHAT IS YOUR DIAGNOSIS?

Financial support and sponsorship

Nil.

Conflicts of interest

There are no conflicts of interest.

Received: 12-11-2018 Accepted: 25-12-2018 Available Online: 17-05-2019

Access this article online

Quick Response Code:



Website:
www.jmuonline.org

DOI:
10.4103/JMU.JMU_109_18

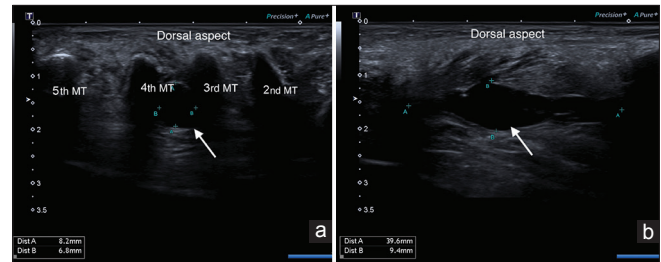


Figure 1: Ultrasound images showing (a) transverse view and (b) longitudinal view of the right dorsal foot (MT: Metatarsal bone, arrow: the lesion)

Address for correspondence:

Dr. Tyng-Guey Wang,
Departments of Physical Medicine and Rehabilitation, College of Medicine,
National Taiwan University Hospital, National Taiwan University,
Taipei, Taiwan.
E-mail: tgw@ntu.edu.tw

This is an open access journal, and articles are distributed under the terms of the Creative Commons Attribution-NonCommercial-ShareAlike 4.0 License, which allows others to remix, tweak, and build upon the work non-commercially, as long as appropriate credit is given and the new creations are licensed under the identical terms.

For reprints contact: reprints@medknow.com

How to cite this article: Cheng SH, Wang TG. A 51-year-old woman with right dorsal foot pain. J Med Ultrasound 2019;27:117.